

表1. EUS-FNA関連手技件数推移

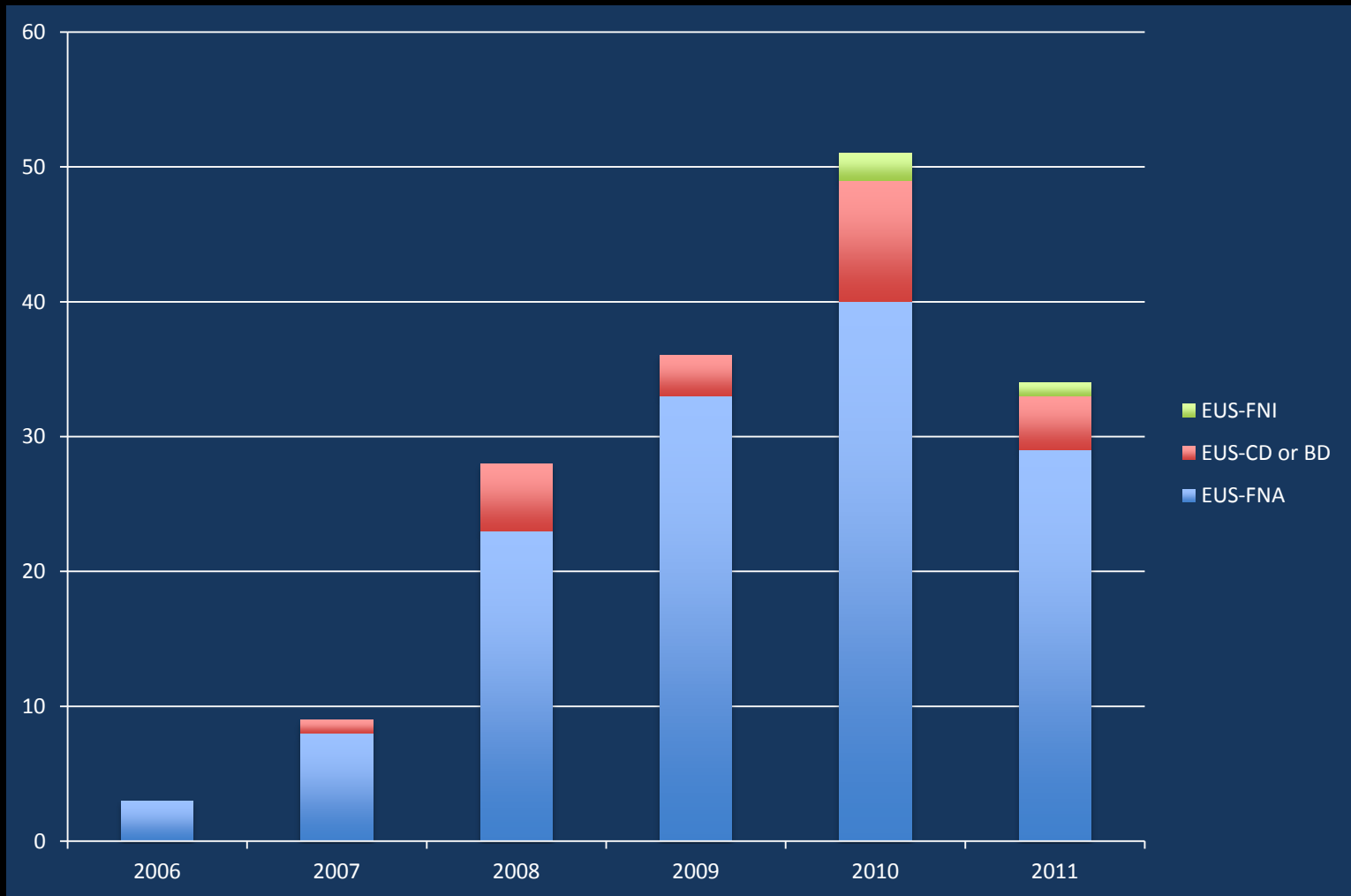
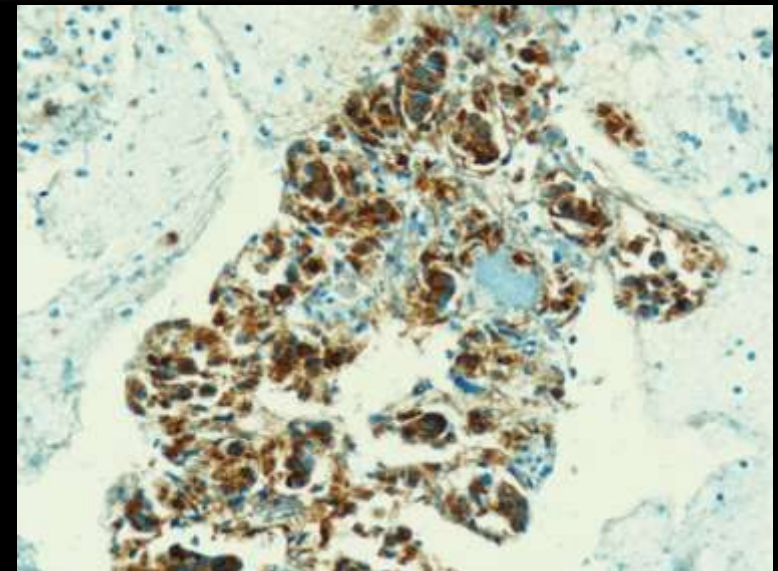
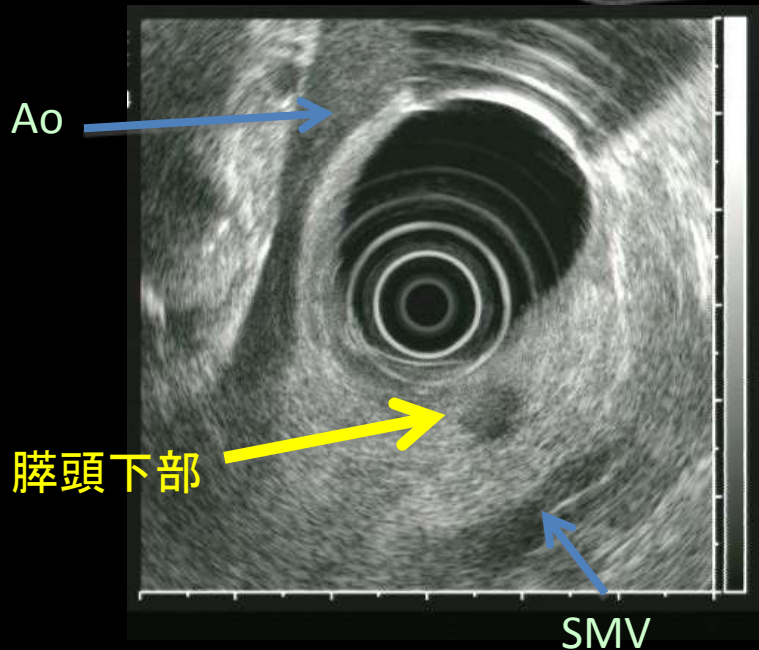
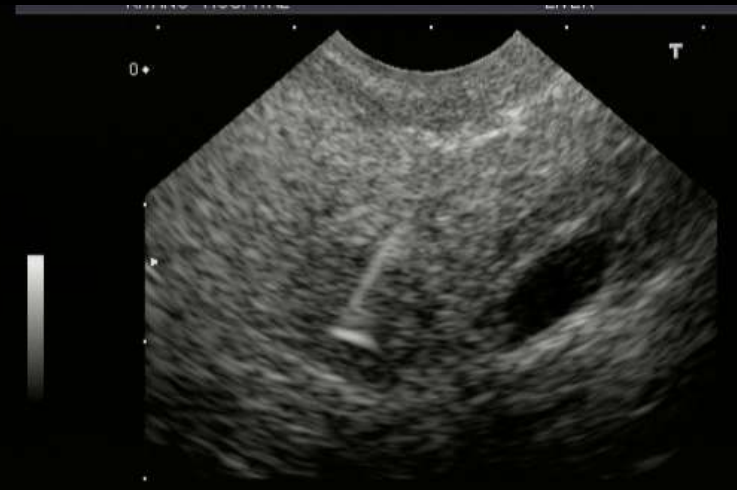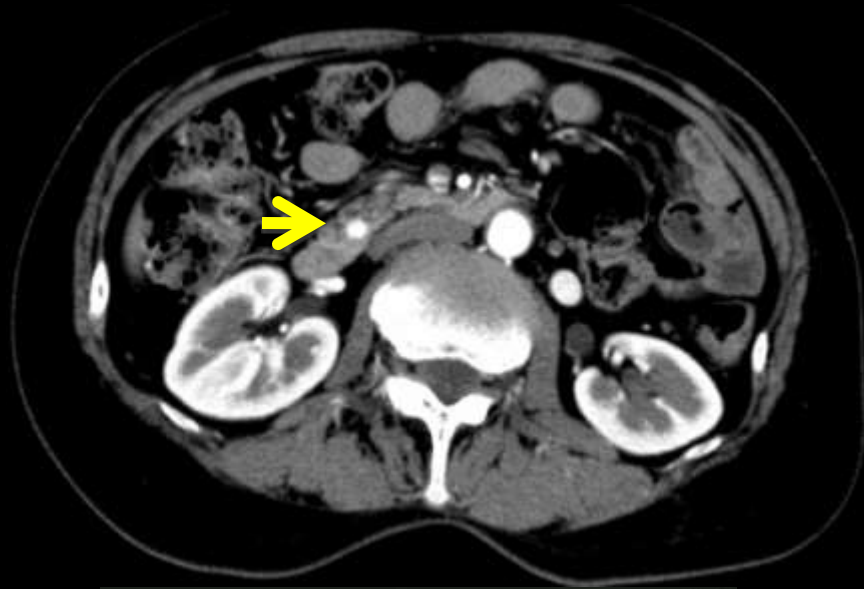


図1. 膵頭下部の内分泌腫瘍



Chromogranin A

図2. 腹腔内リンパ節と細胞診

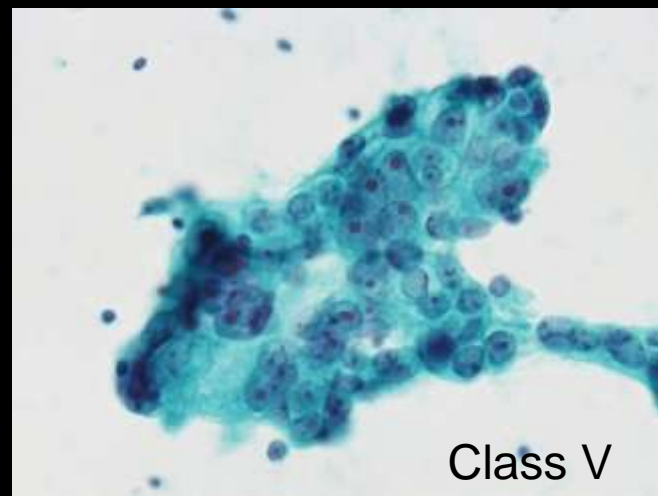
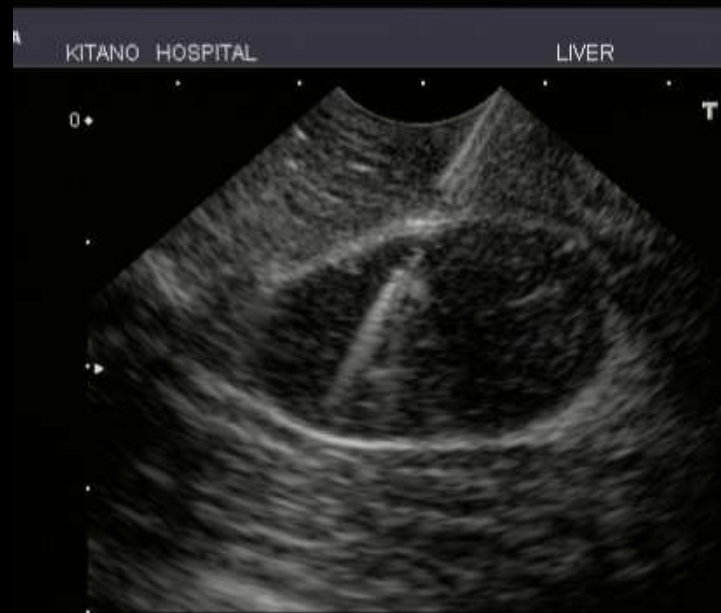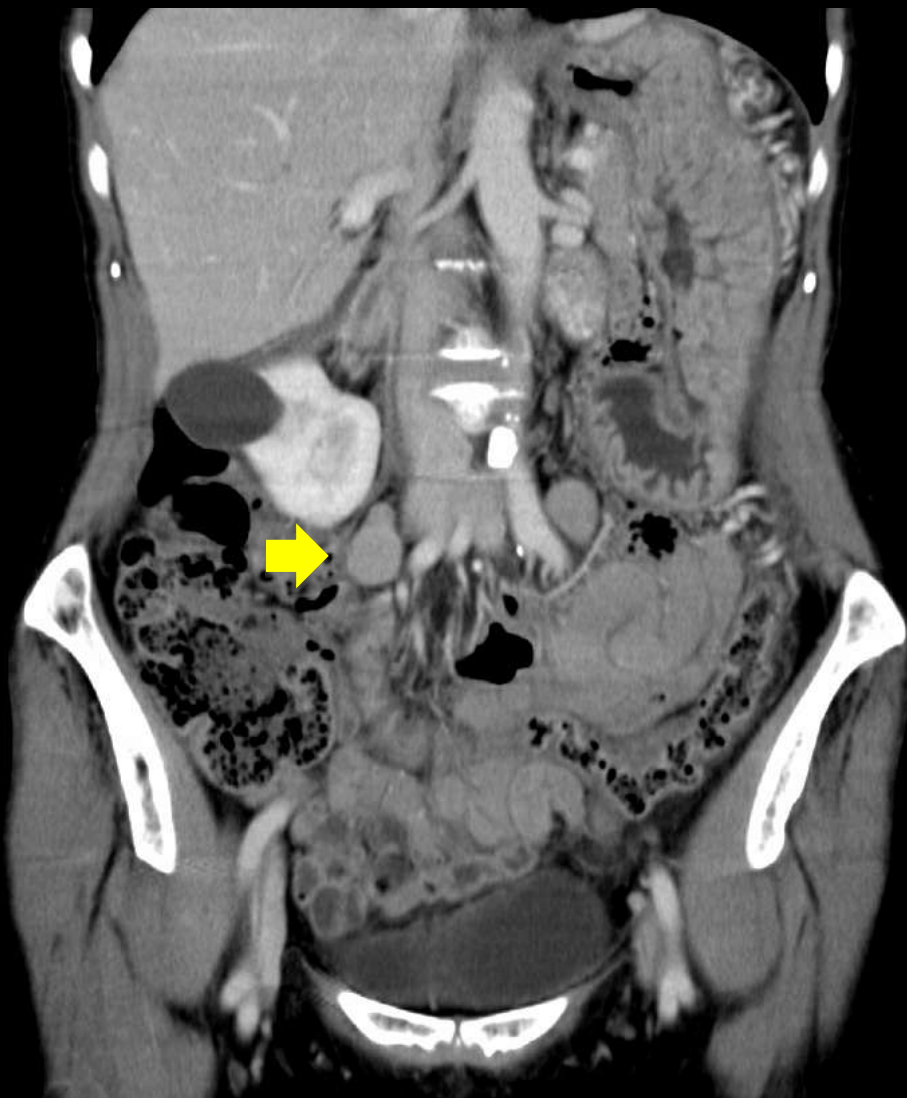
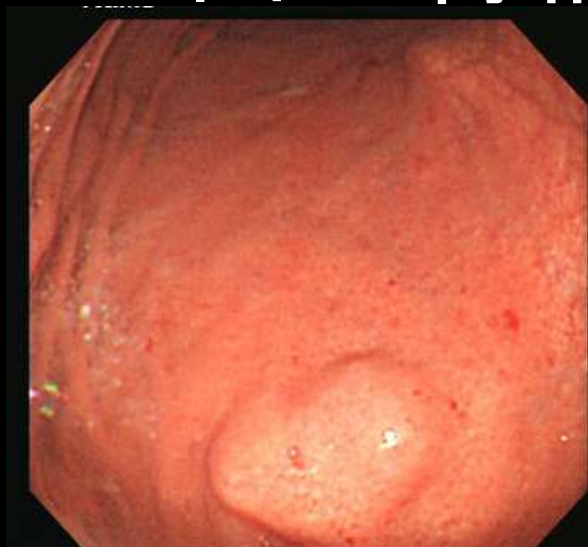
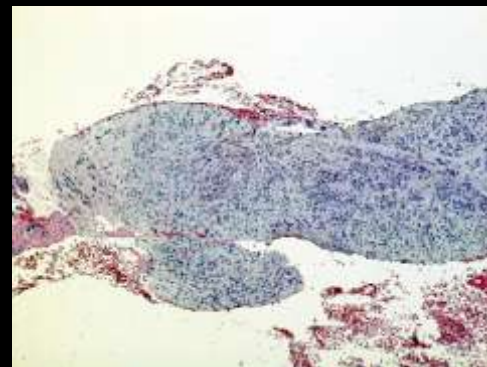


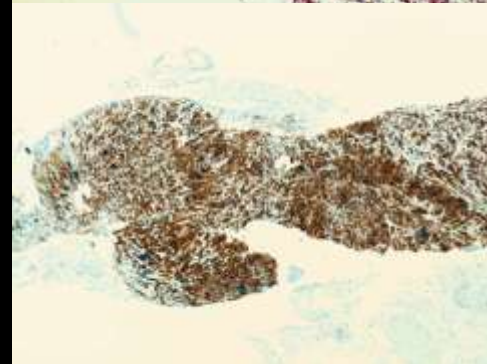
图3. 胃粘膜下肿瘤 (GIST)



HE



c-kit



CD34

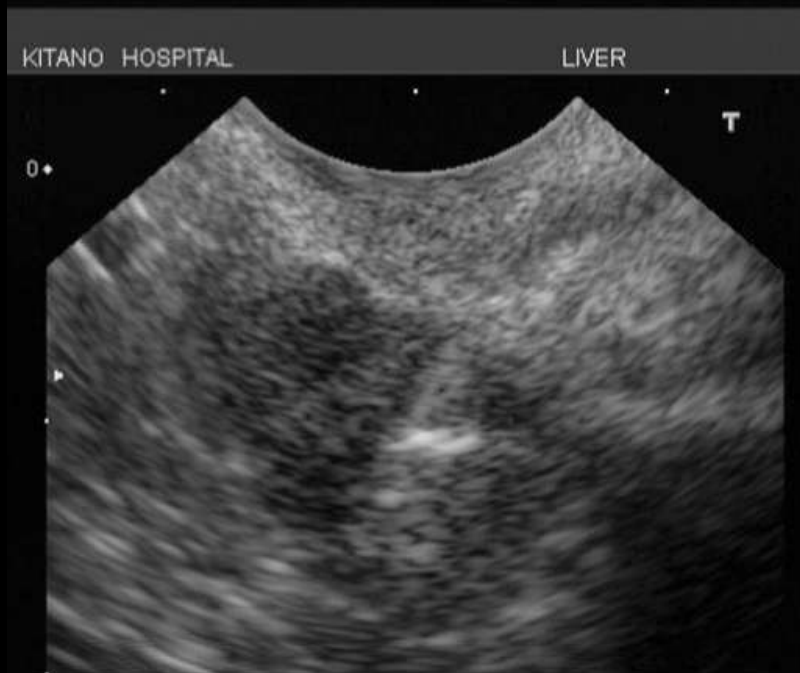
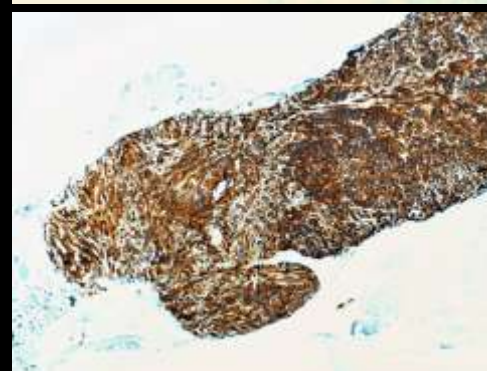
表3. 当院での胃粘膜下腫瘍の治療方針

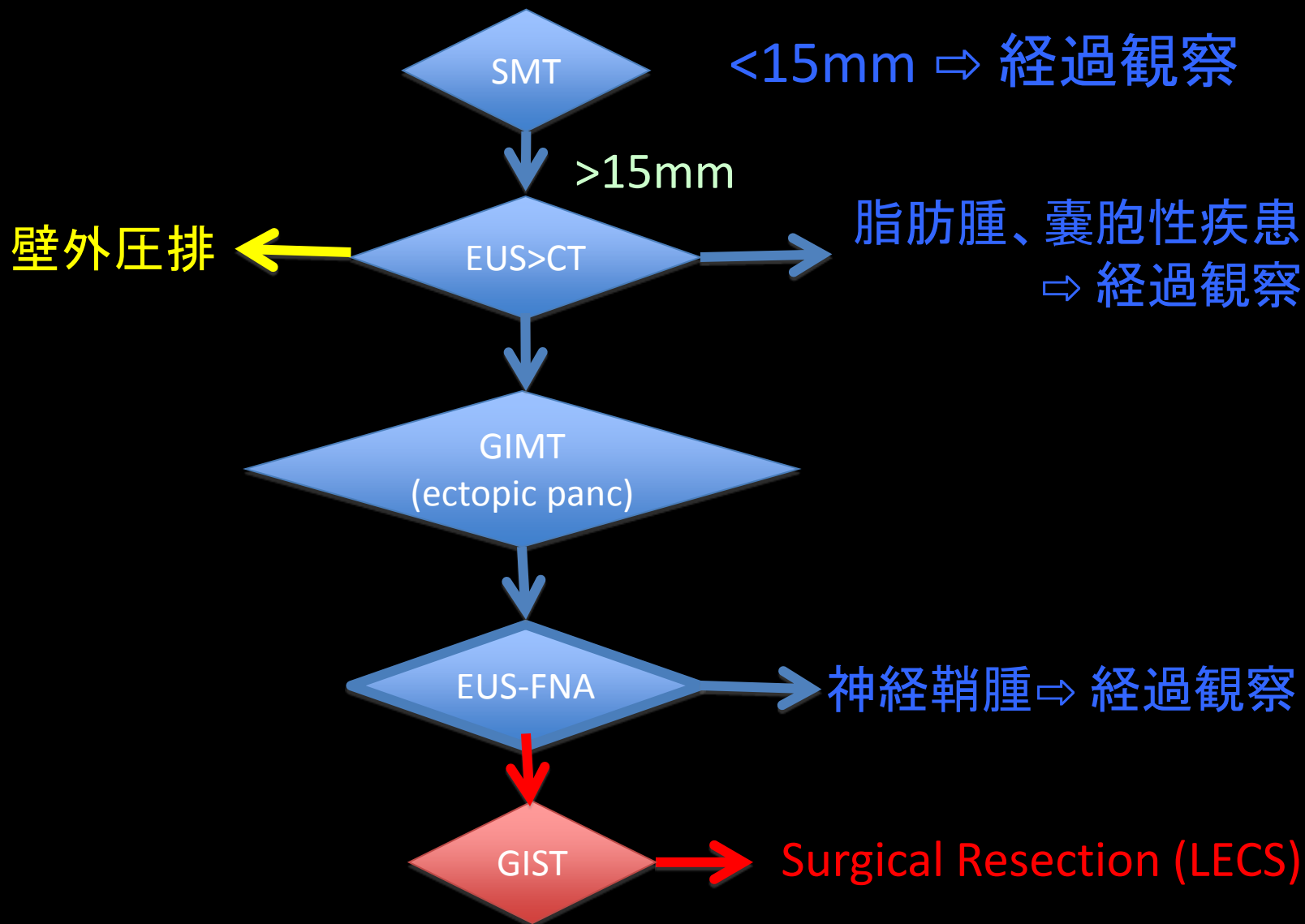
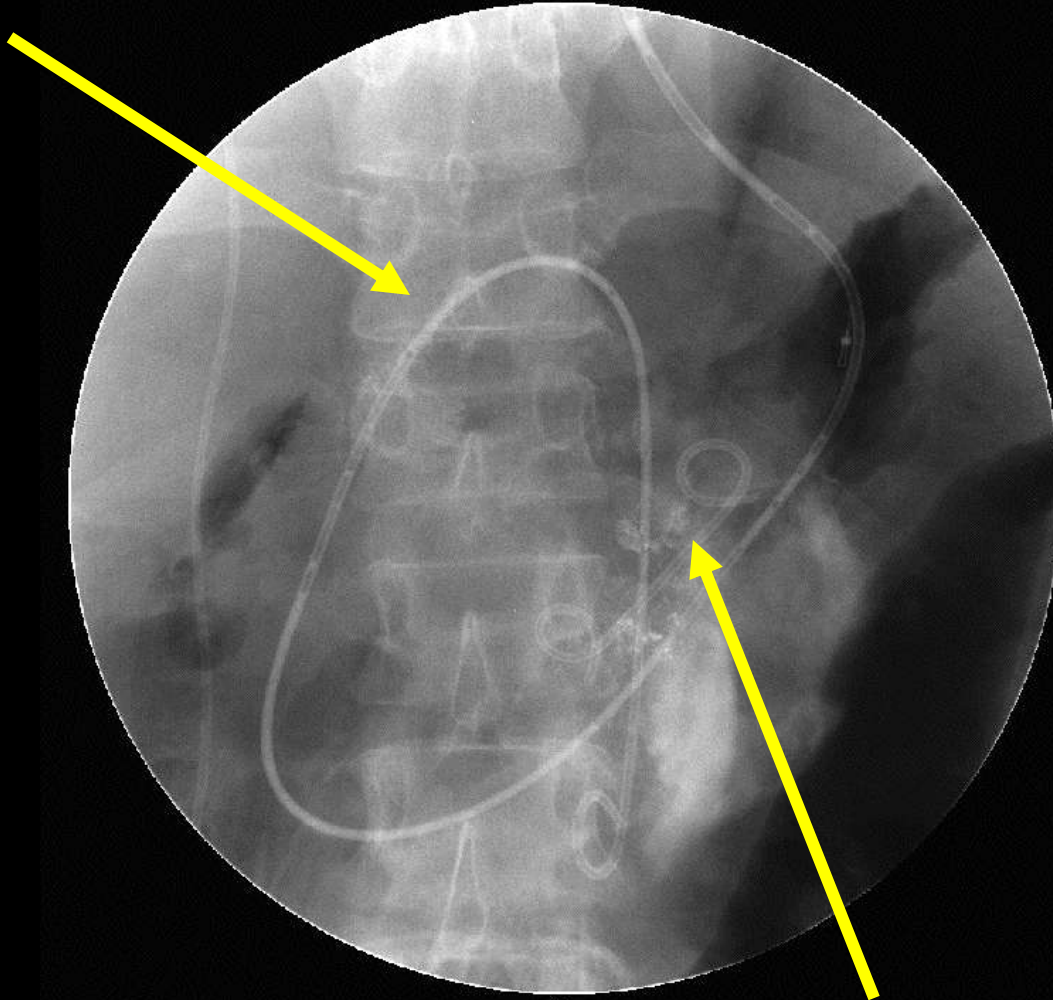


図4. 感染性腭仮性嚢胞の内視鏡的治療

ENCD: endoscopic nasocystic drainage

7 Fr pigtail



ECG: endoscopic cyst-gastrostomy 7 Fr x 4 cm pigtail

図5. 感染性臍仮性嚢胞の内視鏡的治療

